

Conference Case

# Relapsed refractory nodal peripheral T-cell lymphoma with follicular helper T-cell phenotype was initially resistant to pralatrexate and confirmed to be unresponsive to subsequent forodesine, but responded to re-instituted pralatrexate

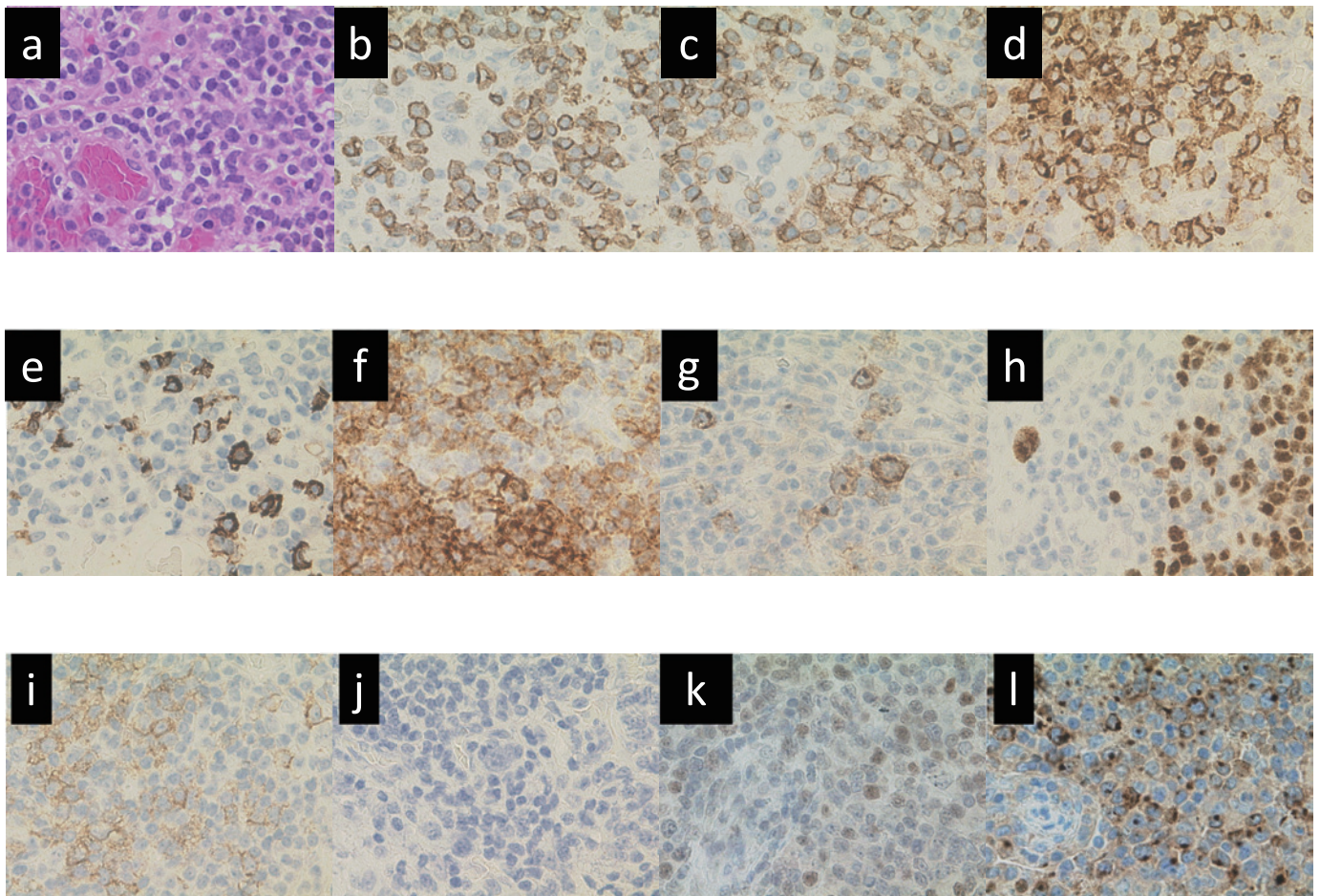
**Keywords:** Peripheral T-cell lymphoma (PTCL), Pralatrexate (PDX), Forodesine, Relapse/Refractory, Retreatment

## CASE REPORT

The patient was a 79-year-old Japanese female. She developed multiple areas of swelling in the right axilla and bilateral neck lymph nodes (LNs), in addition to loss of appetite and night sweats. She was diagnosed with peripheral T-cell lymphoma, not otherwise specified (PTCL, NOS) with Ann Arbor clinical stage of IIIB, International Prognostic Score (IPI) of high intermediate (HI) and prognostic index for PTCL-U (PIT) score of 2. Six cycles of CHOP (cyclophosphamide, doxorubicin, vincristine and prednisolone) were administered and complete remission (CR) was confirmed by F18-fluorodeoxyglucose-positron emission tomography/computed tomography (FDG-PET/CT). After 8 years of remission, she presented with multiple swollen superficial LNs. Left cervical LN biopsy yielded the diagnosis of nodal peripheral T-cell lymphoma with follicular helper T-cell phenotype (nodal PTCL with TFH phenotype) (Figure 1). On immunohistochemistry, the lymphoma cells were positive for CD2, CD3, CD4, CD5, CD7, CD10, PD1 and CCR4, and negative for CD8, CD20 and TIA1. There was no evidence of bone marrow or CNS invasion. She was administered 6 cycles of CVP (cyclophosphamide, vincristine and prednisolone), resulting in CR, but she presented again with multiple superficially swollen LNs 7 months after the first relapse. Lymph node biopsy yielded the diagnosis of relapsed nodal PTCL with TFH phenotype and mogamulizumab (1 mg/kg) was started. The LNs transiently decreased in size but became swollen again just prior to completion of the first cycle. Therefore, she was started on pralatrexate (PDX) at 30 mg/m<sup>2</sup>. As reduction of the swollen LNs was evident during the initial cycle of the new regimen, PDX was continued for a second cycle. However, the LNs started to increase in size again and only a reduction in the size of the swollen axillary LNs was evident. The regimen was switched to forodesine at 600 mg/day, which exacerbated the disease. As the efficacy of PDX was maintained for some lesions (e.g., swollen axillary LNs), forodesine was switched again to PDX at 30 mg/m<sup>2</sup>. The LNs rapidly decreased in size in response to PDX. As she developed severe stomatitis

(grade 4 according to CTCAE version 4.0) after the second dose, PDX was discontinued. She died of concurrent pneumonia 18 months after the first relapse. No swollen LNs were found on postmortem examination; PDX response was rated as CR.

PTCL is an aggressive, heterogeneous disease that includes many subtypes of mature T- and natural killer-cell neoplasms, and accounts for 5-10% of all non-Hodgkin lymphomas in North America and Europe.<sup>1</sup> The disease often accounts for a higher percentage of cases, i.e., approximately 20% in Asia, including Japan.<sup>2</sup> No standard treatment has been established. CHOP or CHOP-like regimens are often selected for initial treatment.<sup>3</sup> The CR rate ranges from 50% to 70%, but relapse is not infrequent and the long-term prognosis is unfavorable.<sup>1</sup> The median survival time after relapse is poor, i.e., only 5.5 to 6 months;<sup>4</sup> therefore, countermeasures to treat relapse are urgently needed. Chihara and colleagues reported that the long-term prognosis improves after hematopoietic stem cell transplantation (SCT) in post-relapse PTCL.<sup>5</sup> The 5-year survival rate was 32% in patients with autologous SCT, 52% with allogeneic SCT and 10% without SCT. New drugs have become available in recent years for the treatment of recurrent PTCL. They include pralatrexate,<sup>6</sup> forodesine,<sup>7</sup> romidepsin,<sup>8</sup> mogamulizumab<sup>9</sup> and brentuximab.<sup>10</sup> Regarding the effects of these drugs, the overall response rate (ORR) of 0 to 54%,<sup>6-10</sup> median response duration of 3 to 28 months and median survival time of 6 to 14.5 months are unsatisfactory. The only method to obtain a long-term sustained response was considered to be the successive use of these new drugs in clinical practice. However, there is no evidence regarding proper use of these new drug regimens. It also remains unclear how the therapeutic response and pharmacological effects vary with the sequence of use of new drug regimens. In this case, re-instituted PDX was effective, although the underlying reason remains unclear. The possibility that forodesine affected on the pharmacological effects of PDX cannot be excluded because the response to the re-instituted PDX occurred after forodesine. As for adverse events, stomatitis, which did not develop during the initial therapy with PDX, developed in a



**Fig. 1.** Lymph node in the first relapse ( $\times 400$ )  
 Sheet-like growth of medium-to-large atypical cells with irregular nuclear shapes was observed (*a*, HE). On immunohistochemistry, the lymphoma cells were CD3-positive (*b*), CD4-positive (*c*), CD10-focally positive (*d*), CD20-negative (*e*), PD1-focally positive (*i*), EBER-negative (*j*), BCL6-positive (*k*) and CXCL13-positive (*l*). Proliferation of follicular dendritic cells (FDC) was noted on immunohistochemistry with CD21 (*f*). Hodgkin-Reed Sternberg-like B-cells were positive for CD30 (*g*) and PAX-5 (*h*).

severe form following re-institution of PDX. Furthermore, it was thought to be important to prevent the development of infections due to neutropenia and lymphopenia. In an *in vitro* study reported by Oiwa *et al.*, a PTCL cell line that had become resistant to PDX after exposure to PDX exhibited increased susceptibility to forodesine, although the underlying reason remained unclear.<sup>11</sup> However, exposure to the drugs was in the reverse sequence in the present case. Thus, the possibility that PDX and forodesine affect the pharmacological effects of each other cannot be excluded.

## CONFLICT OF INTEREST

Disclosure of conflict of interest: None.

## REFERENCES

- 1 Vose J, Armitage J, Weisenburger D; International T-Cell Lymphoma Project. International peripheral T-cell and natural killer/T-cell lymphoma study: pathology findings and clinical outcomes. *J Clin Oncol.* 2008; 26 : 4124-4130.
- 2 Park S, Ko YH. Peripheral T cell lymphoma in Asia. *Int J Hematol.* 2014; 99 : 227-239.
- 3 NCCN Clinical practice guidelines in oncology. T-cell lymphomas Version 3. 2018. <http://WWW.nccn.org>. Accessed 9 August 2018.
- 4 Ellin F, Landström J, Jerkeman M, Relander T. Real-world data on prognostic factors and treatment in peripheral T-cell lymphomas: a study from the Swedish Lymphoma Registry. *Blood.* 2014; 124 : 1570-1577.
- 5 Chihara D, Fanale MA, Miranda RN, *et al.* The survival outcome of patients with relapsed/refractory peripheral T-cell lymphoma-not otherwise specified and angioimmunoblastic T-cell lymphoma. *Br J Haematol.* 2017; 176 : 750-758.
- 6 O'Connor OA, Pro B, Pinter-Brown L, *et al.* Pralatrexate in patients with relapsed or refractory peripheral T-cell lymphoma: results from the pivotal PROPEL study. *J Clin Oncol.* 2011; 29 : 1182-1189.
- 7 Makita S, Maeshima AM, Maruyama D, Izutsu K, Tobinai K. Forodesine in the treatment of relapsed/refractory peripheral T-cell lymphoma: an evidence-based review. *OncoTargets Ther.* 2018; 11 : 2287-2293.
- 8 Maruyama D, Tobinai K, Ogura M, *et al.* Romidepsin in Japanese patients with relapsed or refractory peripheral T-cell

- lymphoma: a phase I/II and pharmacokinetics study. *Int J Hematol.* 2017; 106 : 655-665.
- 9 Ogura M, Ishida T, Hatake K, *et al.* Multicenter phase II study of mogamulizumab (KW-0761), a defucosylated anti-cc chemokine receptor 4 antibody, in patients with relapsed peripheral T-cell lymphoma and cutaneous T-cell lymphoma. *J Clin Oncol.* 2014; 32 : 1157-1163.
  - 10 Pro B, Advani R, Brice P, *et al.* Five-year results of brentuximab vedotin in patients with relapsed or refractory systemic anaplastic large cell lymphoma. *Blood.* 2017; 130 : 2709-2717.
  - 11 Oiwa K, Hosono N, Nishi R, O'Connor O, Yamauchi T. Generation and Characterization of pralatrexate-resistant cell line. 10th Annual T-cell lymphoma forum.

**Yasunobu Sekiguchi,<sup>1)</sup> Mutsumi Wakabayashi,<sup>1)</sup>  
Haruko Takizawa,<sup>1)</sup> Hiroko Iizuka,<sup>1)</sup>  
Sakura Sakajiri,<sup>1)</sup> Keiji Sugimoto,<sup>1)</sup>  
Tadaaki Inano,<sup>2)</sup> Yasutaka Fukuda,<sup>2)</sup>  
Yasuharu Hamano,<sup>2)</sup> Shigeki Tomita,<sup>3)</sup>  
Hiroshi Izumi,<sup>3)</sup> Mitsuo Okubo,<sup>4)</sup>  
Noriko Nakamura,<sup>5)</sup> Tomohiro Sawada,<sup>5)</sup>  
Norio Komatsu,<sup>2)</sup> Masaaki Noguchi<sup>1)</sup>**

<sup>1)</sup>Department of Hematology, Urayasu-shi, Japan, <sup>3)</sup>Division of Diagnostic Pathology, Urayasu-shi, Japan, <sup>4)</sup>Laboratory of Blood Transfusion, Urayasu-shi, Japan, <sup>5)</sup>Department of Laboratory Medicine, Juntendo University Urayasu Hospital, Urayasu-shi, Japan, <sup>2)</sup>Department of Hematology, Juntendo University Hospital Bunkyo-ku, Japan  
**Corresponding author:** Yasunobu Sekiguchi, Department of Hematology, Juntendo University Urayasu Hospital, 1-1, Tomioka 2-chome, Urayasu, Chiba Prefecture.  
E-mail: [yasu\\_sek@juntendo-urayasu.jp](mailto:yasu_sek@juntendo-urayasu.jp)


Received: August 28, 2018.

Accepted: January 15, 2020.

Online Published: March 28, 2020

DOI:10.3960/jslrt.18031

Copyright © 2020 The Japanese Society for Lymphoreticular Tissue Research

 This work is licensed under a Creative Commons Attribution-NonCommercial-ShareAlike 4.0 International License.